

---

---

**Traditional Chinese medicine —  
Vocabulary for diagnostics —**

**Part 1:  
Tongue**

*Médecine traditionnelle chinoise — Vocabulaire pour les  
diagnostics —*

**iTeh STANDARD PREVIEW**  
*Partie 1: Langue*  
**(standards.iteh.ai)**

ISO 23961-1:2021

<https://standards.iteh.ai/catalog/standards/sist/c851ddcc-c2c2-4dbc-a375-870aea00d590/iso-23961-1-2021>



**iTeh STANDARD PREVIEW**  
**(standards.iteh.ai)**

ISO 23961-1:2021

<https://standards.iteh.ai/catalog/standards/sist/c851ddcc-c2c2-4dbc-a375-870aea00d590/iso-23961-1-2021>



**COPYRIGHT PROTECTED DOCUMENT**

© ISO 2021

All rights reserved. Unless otherwise specified, or required in the context of its implementation, no part of this publication may be reproduced or utilized otherwise in any form or by any means, electronic or mechanical, including photocopying, or posting on the internet or an intranet, without prior written permission. Permission can be requested from either ISO at the address below or ISO's member body in the country of the requester.

ISO copyright office  
CP 401 • Ch. de Blandonnet 8  
CH-1214 Vernier, Geneva  
Phone: +41 22 749 01 11  
Email: [copyright@iso.org](mailto:copyright@iso.org)  
Website: [www.iso.org](http://www.iso.org)

Published in Switzerland

# Contents

	Page
Foreword.....	iv
Introduction.....	v
<b>1 Scope.....</b>	<b>1</b>
<b>2 Normative references.....</b>	<b>1</b>
<b>3 Terms and definitions.....</b>	<b>1</b>
<b>4 Terms related to tongue body.....</b>	<b>2</b>
<b>5 Terms related to tongue coating.....</b>	<b>8</b>
<b>Annex A (informative) Typical tongue images.....</b>	<b>12</b>
<b>Annex B (informative) Tongue diagnosis terms — Chinese, Japanese and Korean characters.....</b>	<b>29</b>
<b>Bibliography.....</b>	<b>35</b>

## iTeh STANDARD PREVIEW (standards.iteh.ai)

[ISO 23961-1:2021](https://standards.iteh.ai/catalog/standards/sist/c851ddcc-c2c2-4dbc-a375-870aea00d590/iso-23961-1-2021)

<https://standards.iteh.ai/catalog/standards/sist/c851ddcc-c2c2-4dbc-a375-870aea00d590/iso-23961-1-2021>

## Foreword

ISO (the International Organization for Standardization) is a worldwide federation of national standards bodies (ISO member bodies). The work of preparing International Standards is normally carried out through ISO technical committees. Each member body interested in a subject for which a technical committee has been established has the right to be represented on that committee. International organizations, governmental and non-governmental, in liaison with ISO, also take part in the work. ISO collaborates closely with the International Electrotechnical Commission (IEC) on all matters of electrotechnical standardization.

The procedures used to develop this document and those intended for its further maintenance are described in the ISO/IEC Directives, Part 1. In particular, the different approval criteria needed for the different types of ISO documents should be noted. This document was drafted in accordance with the editorial rules of the ISO/IEC Directives, Part 2 (see [www.iso.org/directives](http://www.iso.org/directives)).

Attention is drawn to the possibility that some of the elements of this document may be the subject of patent rights. ISO shall not be held responsible for identifying any or all such patent rights. Details of any patent rights identified during the development of the document will be in the Introduction and/or on the ISO list of patent declarations received (see [www.iso.org/patents](http://www.iso.org/patents)).

Any trade name used in this document is information given for the convenience of users and does not constitute an endorsement.

For an explanation of the voluntary nature of standards, the meaning of ISO specific terms and expressions related to conformity assessment, as well as information about ISO's adherence to the World Trade Organization (WTO) principles in the Technical Barriers to Trade (TBT), see [www.iso.org/iso/foreword.html](http://www.iso.org/iso/foreword.html).

This document was prepared by Technical Committee ISO/TC 249, *Traditional Chinese medicine*.

A list of all parts in the ISO 23961 series can be found on the ISO website.

Any feedback or questions on this document should be directed to the user's national standards body. A complete listing of these bodies can be found at [www.iso.org/members.html](http://www.iso.org/members.html).

## Introduction

Traditional Chinese medicine has become increasingly popular all over the world. Traditional Chinese medicine education has developed rapidly. Traditional Chinese medicine has obtained legal status in the United States, Singapore, Australia, Thailand and other countries and regions. Academic activities of traditional Chinese medicine are increasingly active. International communication of traditional Chinese medicine and medical activities, scientific research, management rules and regulations are in urgent need of International Standards.

First, standardized terminology is essential to standardized products and services. Traditional Chinese medicine diagnostic devices are one of the important contents of traditional Chinese medicine diagnosis. This document aims to encourage improvement of tongue-equipment-related industrial and research fields. All traditional Chinese medicine tongue diagnostic instrument can use the same vocabulary, which is very important for international trade and communication. With standardized terminology, the versatility of tongue-equipment-related products or service can be improved to benefit international technical cooperation.

Secondly, the use of standardized terminology in diagnosis helps to avoid confusion among researchers in the field of tongue diagnosis. But more importantly, the use of standardized terminology in tongue diagnosis also helps manufacturers to deliver standardized meaning with measured tongue images for products. Considering the close association between the traditional Chinese medicine diagnosis and diagnostic medical devices, it is not only necessary but also urgent to standardize the diagnostic terminologies.

Third, the purpose of the project is for the use of traditional Chinese medicine diagnostic instruments and artificial intelligence (AI) medicine. As internet-based medicine is developing very quickly, a standardized terminology is not only important for computerized information but also necessary for successful communication between physicians and patients from different countries. With advances in AI, medical AI doctors also need standardized terminology.

Therefore, it is necessary to standardize tongue diagnostic terminology, which will bring benefits to scholars, governments and enterprises all over the world.

**iTeh STANDARD PREVIEW**  
**(standards.iteh.ai)**

ISO 23961-1:2021

<https://standards.iteh.ai/catalog/standards/sist/c851ddcc-c2c2-4dbc-a375-870aea00d590/iso-23961-1-2021>

# Traditional Chinese medicine — Vocabulary for diagnostics —

## Part 1: Tongue

### 1 Scope

This document specifies the basic terminology and classification of tongue diagnostic methods. Each term of tongue diagnosis includes the English name, the classical Chinese characters and its definition.

The classification structure of tongue diagnosis terms is shown in [Figure 1](#).

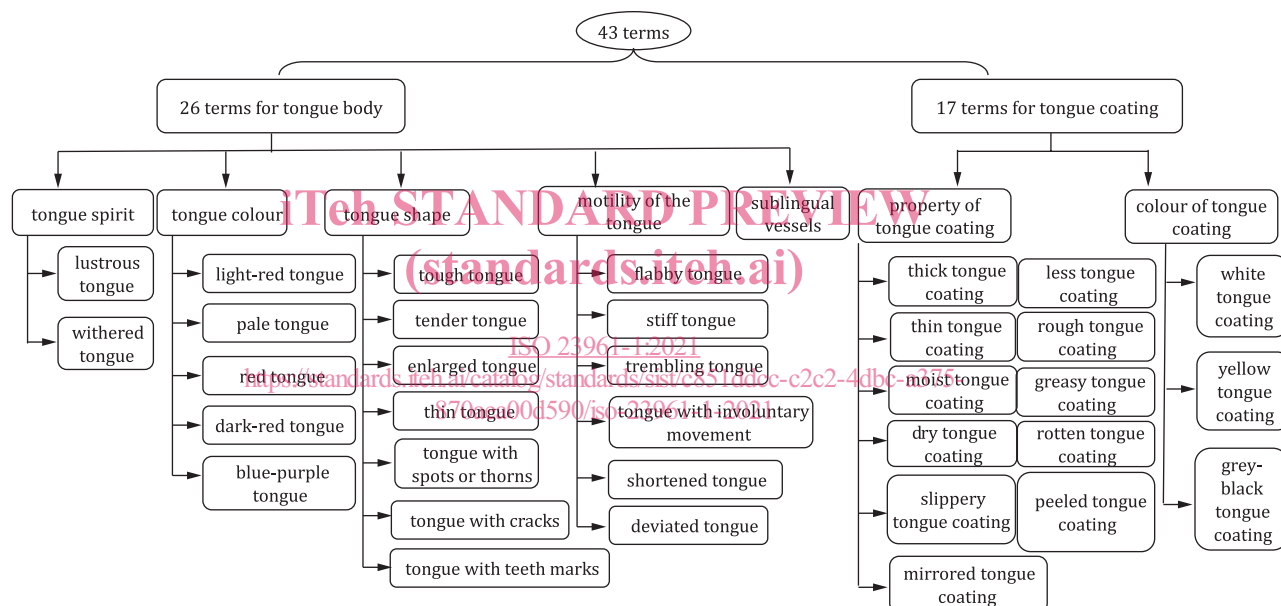


Figure 1 — Classification structure of tongue diagnosis terms

### 2 Normative references

There are no normative references in this document.

### 3 Terms and definitions

ISO and IEC maintain terminological databases for use in standardization at the following addresses:

- ISO Online browsing platform: available at <https://www.iso.org/obp>
- IEC Electropedia: available at <http://www.electropedia.org/>

#### 3.1

##### tongue diagnosis

diagnosis through inspection of the size, shape, colour and moisture of the tongue body and its coating, which helps with understanding the physiological functions and pathological changes of the body

**3.2**

**tongue tip**

frontal end of the tongue body

**3.3**

**tongue centre**

middle part of the tongue body

**3.4**

**tongue root**

back part of the tongue

**3.5**

**tongue edge**

bilateral edge of the dorsal surface of the tongue

**3.6**

**tongue midline groove**

vertical groove in the midline of the tongue body

**3.7**

**lingual frenum**

vertical fold in the midline of the bottom of the tongue

**3.8**

**tongue papillae**

layer of semi-transparent mucosa and tiny projections on the mucosal fold on the tongue surface

iTeh STANDARD PREVIEW  
(standards.iteh.ai)

**4 Terms related to tongue body**

[ISO 23961-1:2021](#)

**4.1**

**tongue body**

舌體

tongue muscles and vessels

<https://standards.iteh.ai/catalog/standards/sist/c851ddcc-c2c2-4dbc-a375-870aea00d590/iso-23961-1-2021>

Note 1 to entry: The first origin is *The Xing Se Wai Zhen Jian Mo* (《形色外診簡摩》).

Note 2 to entry: *The Zhong Yi She Zhen* (《中醫舌診》, *Traditional Chinese Medicine Tongue Diagnosis*) states, “The tongue body refers to the musculature of the tongue, including lingual mucosa, intrinsic muscles and extrinsic muscles.” *The Bian She Zhi Nan* (《辨舌指南》, *The Guide to Differentiation of Tongue Conditions*) states, “The tongue body refers to the muscles of the tongue.”

Note 3 to entry: For further information, see [B.1](#).

**4.1.1**

**tongue spirit**

舌神

general vitality of the tongue manifest in its moisture, lustre and flexibility

Note 1 to entry: For further information, see [B.1.1](#).

**4.1.1.1**

**lustrous tongue**

榮舌

tongue that is red, luxuriant and moist, with flexible movement

Note 1 to entry: The first origin is *The Guide to Differentiation of Tongue Conditions*.

Note 2 to entry: *The Guide to Differentiation of Tongue Conditions* states, “A lustrous tongue is moist and lustrous.”

Note 3 to entry: A typical lustrous tongue image is shown in [Figure A.2.1.1](#) in [Annex A](#).



Note 4 to entry: For further information, see [B.1.1.1](#).

#### 4.1.1.2

##### withered tongue

枯舌

tongue that is dry, dull, lustreless and grey-dark with inflexible movement

Note 1 to entry: The first origin is *The Shang Han Zhi Zhang* (《傷寒指掌》, *A Handbook on Cold Damage*).

Note 2 to entry: *The Guide to Differentiation of Tongue Conditions* states, “A withered tongue is dry and has no spirit.”

Note 3 to entry: A typical withered tongue image is shown in [Figure A.2.1.2](#) in [Annex A](#).

Note 4 to entry: For further information, see [B.1.1.2](#).

#### 4.1.2

##### tongue colour

舌色

visual hue of the tongue body

Note 1 to entry: The five tongue colours are light-red, pale, red, dark-red and blue-purple.

Note 2 to entry: The first origin is *The Ao Shi Shang Han Jin Jing Lu* (《敖氏傷寒金鏡錄》, *The Ao's Golden Mirror Records for Cold Damage*).

Note 3 to entry: For further information, see [B.1.2](#).

#### 4.1.2.1

##### light-red tongue

淡紅舌

tongue with redness hidden in the whiteness

Note 1 to entry: The first origin is *The Ao's Golden Mirror Records for Cold Damage*.  
<https://standards.iteh.ai/catalog/standards/sist/c851ddcc-c2c2-4dbc-a375-870aca006590/iso-23961-1-2021>

Note 2 to entry: *The Traditional Chinese Medicine Tongue Diagnosis* states, “A light-red tongue is pale red, moist and lustrous. It indicates normal functioning of the heart in dominating blood vessels and of the stomach in moistening the tongue.”

Note 3 to entry: A typical light-red tongue image is shown in [Figure A.2.2.1](#) in [Annex A](#).

Note 4 to entry: For further information, see [B.1.2.1](#).

#### 4.1.2.2

##### pale tongue

淡白舌

tongue lighter or less red than a normal tongue

Note 1 to entry: The first origin is *The Ao's Golden Mirror Records for Cold Damage*.

Note 2 to entry: *The Traditional Chinese Medicine Tongue Diagnosis* states, “A pale tongue appears more whitish and less red, or even entirely without red colour.” *The She Tai Tong Zhi* (《舌胎統誌》, *Outlines of Tongue Coating*) states, “A pale tongue is usually seen in pathological conditions. It is paler than a normal tongue and slightly redder than a withered white tongue.”

Note 3 to entry: A typical pale tongue image is shown in [Figure A.2.2.2](#) in [Annex A](#).

Note 4 to entry: For further information, see [B.1.2.2](#).

**4.1.2.3**  
**red tongue**

紅舌

tongue redder than a normal tongue

Note 1 to entry: The first origin is *The Ao's Golden Mirror Records for Cold Damage*.

Note 2 to entry: *The Traditional Chinese Medicine Tongue Diagnosis* states, "Light-red is the normal tongue colour. A red tongue is deeper than normal colour. It can be fresh red or dark red." *The She Zhen Yuan Jian* (《舌診源鑒》, *The Source and Differentiation of the Tongue Conditions*) states, "A red tongue is redder and deeper than a normal light-red tongue, appearing red like blood."

Note 3 to entry: A typical red tongue image is shown in [Figure A.2.2.3](#) in [Annex A](#).

Note 4 to entry: For further information, see [B.1.2.3](#).

**4.1.2.4**  
**dark-red tongue**

絳舌

tongue deep red in colour

Note 1 to entry: The first origin is *The Ao's Golden Mirror Records for Cold Damage*.

Note 2 to entry: *The Outlines of Tongue Coating* states, "A dark-red tongue appears crimson, just like the colour of the fire." *The Guide to Differentiation of Tongue Conditions* states, "A dark-red tongue is deep red." *The Source and Differentiation of the Tongue Conditions* states, "A dark-red tongue is darker than a red tongue, appearing cinnabar."

Note 3 to entry: A typical dark-red tongue image is shown in [Figure A.2.2.4](#) in [Annex A](#).

Note 4 to entry: For further information, see [B.1.2.4](#).

**4.1.2.5**  
**blue-purple tongue**

青紫舌

tongue appearing bluish or purple in the whole tongue or parts of the tongue

Note 1 to entry: The first origin is *The Ao's Golden Mirror Records for Cold Damage*.

Note 2 to entry: *The Traditional Chinese Medicine Tongue Diagnosis* states, "A blue or purple tongue is pale-blue or pale-purple and moist."

Note 3 to entry: A typical blue-purple tongue image is shown in [Figure A.2.2.5](#) in [Annex A](#).

Note 4 to entry: For further information, see [B.1.2.5](#).

**4.1.3**  
**tongue shape**

舌形

shape of the tongue body

Note 1 to entry: Tongue shape includes such aspects as tough or tender, enlarged or thin, spots or thorns, cracks and teeth marks.

Note 2 to entry: The first origin is *The Handbook on Cold Damage*.

Note 3 to entry: For further information, see [B.1.3](#).

**4.1.3.1**  
**tough tongue**

老舌

tongue with a rough or crimped texture

Note 1 to entry: The first origin is *The Ao's Golden Mirror Records for Cold Damage*.

iTeh STANDARD PREVIEW  
(standards.iteh.ai)

ISO 23961-1:2021  
<https://standards.iteh.ai/catalog/standards/sist/c851ddcc-c2c2-4dbc-a375-870aea00d590/iso-23961-1-2021>

Note 2 to entry: A typical tough tongue image is shown in [Figure A.2.3.1](#) in [Annex A](#).

Note 3 to entry: For further information, see [B.1.3.1](#).

#### 4.1.3.2 tender tongue

嫩舌

tongue with a delicate and fine texture

Note 1 to entry: The first origin is *The Ao's Golden Mirror Records for Cold Damage*.

Note 2 to entry: A typical tender tongue image is shown in [Figure A.2.3.2](#) in [Annex A](#).

Note 3 to entry: For further information, see [B.1.3.2](#).

#### 4.1.3.3 enlarged tongue

胖大舌

tongue that is bigger and thicker than a normal tongue

Note 1 to entry: The first origin is *The Wan Jin Zhi Bao* (《萬金至寶》).

Note 2 to entry: *The Guide to Differentiation of Tongue Conditions* states, "An enlarged tongue is so swollen and enlarged that it cannot be extended out of the mouth." *The Wan Jin Zhi Bao* states, "An enlarged tongue is just like the swim bladder."

Note 3 to entry: A typical enlarged tongue image is shown in [Figure A.2.3.3](#) in [Annex A](#).

Note 4 to entry: For further information, see [B.1.3.3](#).

#### 4.1.3.4 thin tongue

瘦薄舌

tongue that is smaller and thinner than a normal tongue

Note 1 to entry: A typical thin tongue image is shown in [Figure A.2.3.4](#) in [Annex A](#).

Note 2 to entry: For further information, see [B.1.3.4](#).

#### 4.1.3.5 tongue with spots or thorns

點刺舌

tongue with red or purple stars (bigger ones) or spots (smaller ones) as well as awn-shaped thorns higher above the tongue surface

Note 1 to entry: The first origin is *The Ao's Golden Mirror Records for Cold Damage*.

Note 2 to entry: *The Ao's Golden Mirror Records for Cold Damage* states, "A red-star tongue refers to the tongue with big red spots." *The Shang Han She Jian* (《傷寒舌鑿》, *Differentiation of the Tongue Conditions in Exogenous Febrile Diseases*) states, "Sometimes the tongue may have big red stars (bigger ones) or big red spots (smaller ones); sometimes the tongue may have red or purple thorns."

Note 3 to entry: A typical tongue with spots and thorns image is shown in [Figure A.2.3.5](#) in [Annex A](#).

Note 4 to entry: For further information, see [B.1.3.5](#).

#### 4.1.3.6 tongue with cracks

裂紋舌

tongue with a variety of shallow or deep cracks

Note 1 to entry: The first origin is *The Ao's Golden Mirror Records for Cold Damage*.

Note 2 to entry: *The Cha She Bian Zheng Xin Fa* (《察舌辨癥新法》, *New Methods in Syndrome Differentiation through Tongue Observation*) states, “A tongue with cracks may have sagittal straight grooves on the surface of the tongue, just like imprinted by the back of a knife blade. Sometimes, the tongue may have transverse cracks on the surface of the tongue.” *The She Jian Bian Zheng* (《舌鑿辨正》, *Syndrome Differentiation through Tongue Observation*) states, “A cracked tongue may have herringbone fissures.” *The Guide to Differentiation of Tongue Conditions* states, “Cracks on the surface of the tongue may resemble the shapes of Chinese characters ‘人’, ‘川’ and ‘爻’, or sometimes just like straight grooves.”

Note 3 to entry: A typical tongue with cracks image is shown in [Figure A.2.3.6](#) in [Annex A](#).

Note 4 to entry: For further information, see [B.1.3.6](#).

#### 4.1.3.7

##### **tongue with teeth marks**

齒痕舌

tongue with dental indentations at the edges

Note 1 to entry: The first origin is *The Guide to Differentiation of Tongue Conditions*.

Note 2 to entry: *The Guide to Differentiation of Tongue Conditions* states, “A tongue with teeth marks means there are teeth marks at both sides of the tongue.”

Note 3 to entry: A typical tongue with teeth marks image is shown in [Figure A.2.3.7](#) in [Annex A](#).

Note 4 to entry: For further information, see [B.1.3.7](#).

#### 4.1.4

##### **motility of the tongue**

舌態

ability of the tongue to move spontaneously

iTeh STANDARD PREVIEW  
(standards.iteh.ai)

Note 1 to entry: For further information, see [B.1.4](#) [ISO 23961-1:2021](#)

<https://standards.iteh.ai/catalog/standards/sist/c851ddcc-c2c2-4dbc-a375-870aea00d590/iso-23961-1-2021>

#### 4.1.4.1

##### **flabby tongue**

痿軟舌

tongue that is limp, wilting and cannot extend or retract freely

Note 1 to entry: The first origin is *The Differentiation of the Tongue Conditions in Exogenous Febrile Diseases*.

Note 2 to entry: *The Differentiation of the Tongue Conditions in Exogenous Febrile Diseases* states, “A flabby tongue is floppy, soft and unable to move flexibly.” *The Syndrome Differentiation through Tongue Observation* states, “A flabby tongue is floppy, soft and unable to move flexibly.”

Note 3 to entry: A typical flabby tongue image is shown in [Figure A.2.4.1](#) in [Annex A](#).

Note 4 to entry: For further information, see [B.1.4.1](#).

#### 4.1.4.2

##### **stiff tongue**

強硬舌

tongue that is unable to do flexion, extension or rotation

Note 1 to entry: The first origin is *The New Methods in Syndrome Differentiation through Tongue Observation*.

Note 2 to entry: *The New Methods in Syndrome Differentiation through Tongue Observation* states, “A stiff tongue is unable to move flexibly, coupled with slurred speech.”

Note 3 to entry: A typical stiff tongue image is shown in [Figure A.2.4.2](#) in [Annex A](#).

Note 4 to entry: For further information, see [B.1.4.2](#).

#### 4.1.4.3 deviated tongue

歪斜舌

tongue that inclines to either the left side or the right side when extended

Note 1 to entry: The first origin is *The Guide to Differentiation of Tongue Conditions*.

Note 2 to entry: *The Guide to Differentiation of Tongue Conditions* states, “A deviated tongue is deviated towards either the left or right.”

Note 3 to entry: A typical deviated tongue image is shown in [Figure A.2.4.3](#) in [Annex A](#).

Note 4 to entry: For further information, see [B.1.4.3](#).

#### 4.1.4.4 trembling tongue

顫動舌

tongue that quivers or twitches uncontrollably

Note 1 to entry: The first origin is *The Differentiation of the Tongue Conditions in Exogenous Febrile Diseases*.

Note 2 to entry: *The Differentiation of the Tongue Conditions in Exogenous Febrile Diseases* states, “A trembling tongue quivers or twitches uncontrollably.” *The Syndrome Differentiation through Tongue Observation* states, “A trembling tongue keeps quivering or twitching uncontrollably.” *The Guide to Differentiation of Tongue Conditions* states, “A trembling tongue uncontrollably quivers or twitches.”

Note 3 to entry: For further information, see [B.1.4.4](#).

#### 4.1.4.5 tongue with involuntary movement

吐弄舌

pathological condition in which the tongue extends out of the mouth and does not retract for a long period of time or a playful tongue that is extended and licks the lips (and then is quickly retracted)

Note 1 to entry: The first origin is *The Yi Zong Jin Jian* (《醫宗金鑒》).

Note 2 to entry: *The Guide to Differentiation of Tongue Conditions* states, “A tongue with involuntary movement includes the following two conditions: a protruding tongue that is extended out of the mouth and not retracted for a long period of time and a playful tongue that is extended and licks the lips (and then is quickly retracted).” *The Yi Zong Jin Jian* states, “Tongue with involuntary movement is extended out of the mouth but not retracted for a long period of time.” *The Differentiation of the Tongue Conditions in Exogenous Febrile Diseases* states, “A playful tongue is repeatedly extended and quickly retracted.” *The Syndrome Differentiation through Tongue Observation* states, “... So the tongue is frequently extended out of the mouth and quickly retracted, or sometimes it repeatedly licks the lips, corners of the mouth and nasal tip.”

Note 3 to entry: Typical tongue with involuntary movement images are shown in [Figure A.2.4.4](#) in [Annex A](#).

Note 4 to entry: For further information, see [B.1.4.5](#).

#### 4.1.4.6 shortened tongue

短縮舌

tongue that is contracted with a tightened tongue frenum and unable to extend out of the mouth

Note 1 to entry: The first origin is *The New Methods in Syndrome Differentiation through Tongue Observation*.

Note 2 to entry: *The New Methods in Syndrome Differentiation through Tongue Observation* states, “A shortened tongue is unable to extend out of the mouth.” *The Guide to Differentiation of Tongue Conditions* states, “A shortened tongue is contracted with tightened tongue frenum and unable to extend out of the mouth.”

Note 3 to entry: A typical shortened tongue image is shown in [Figure A.2.4.5](#) in [Annex A](#).

Note 4 to entry: For further information, see [B.1.4.6](#).